

# Cluster of Fatal Cardiopulmonary Failure among Children Caused by an Emerging Strain of Enterovirus 71, Nakhorn Ratchasima Province, Thailand, 2006

Rome Buathong<sup>1</sup>, Hanshoaworakul W<sup>1</sup>, Sutdan D<sup>1</sup>, Iamsirithaworn S<sup>1</sup>, Pongsuwanna Y<sup>2</sup>, Puthawathana P<sup>3</sup>, O'Reilly M<sup>1,4</sup>, Ungchusak K<sup>1</sup>

<sup>1</sup> International Field Epidemiology Training Program (FETP), Bureau of Epidemiology, Department of Disease Control, Ministry of Public Health (MOPH), Thailand

<sup>2</sup> Enterovirus Section, National Institute of Health (NIH), Department of Medical Science, Ministry of Public Health (MOPH), Thailand

<sup>3</sup> Department of Microbiology, Faculty of Medicine Siriraj Hospital, Mahidol University, Thailand

<sup>4</sup> Thailand MOPH-US CDC Collaboration (TUC)

## Introduction

Enterovirus 71 (EV71) infections have been a public health priority in the Asia-Pacific region since 1998 when a major outbreak of hand, foot and mouth disease (HFMD) and herpangina due to EV71 occurred in Taiwan involving 129,106 cases and 78 deaths<sup>1</sup>. In 2006, Malaysia also experienced a large scale EV71 HFMD outbreak, involving at least 13,800 cases and 13 deaths<sup>2</sup>. Fatal cases in both the Taiwan and Malaysia outbreaks had high rates of brain stem infection and cardiopulmonary failure<sup>3</sup>.

Many different viruses including Coxsackies A, Coxsackies B, Echovirus and Enterovirus 68-71 can cause HFMD, a clinical syndrome characterized by fever and vesicular lesions on the hands, feet and oral mucosa. EV71 is thought to be an important cause of HFMD though manifestation of EV71 is not restricted to HFMD. EV71 infection is most often asymptomatic or mildly symptomatic, but it may cause acute febrile illness, upper respiratory tract infection, gastroenteritis, limb weakness, myocarditis and/or pericarditis, brain stem infection and other illnesses<sup>4,5</sup>.

EV71 was first identified in Thailand in 1998 by positive serology at Sukhothai Province and HFMD was included as a notifiable disease in national surveillance in 2001. Severe HFMD cases, those requiring hospitalization or fatal cases, require investigations that include viral isolation. EV71 was the major cause of HFMD in Thailand between 1998 – 2003 (Table 1), but the yield of EV71 isolation was low (16.7%) compared to other Asian countries<sup>1,6-8</sup>.

Table 1. EV71 isolated in cases of hand, foot and mouth disease in Thailand, 1998-2003

Year	Number of Cases	Viral Isolation or Serology* positive for EV71 (%)
1998	27	2 (7.4)
1999	43	3 (7.0)
2000	186	12 (6.5)
2001†	340	93 (27.4)
2002	420	53 (12.6)
2003	125	28 (22.4)
Total	1,141	191 (16.7)

\* Serology was tested for EV71 only in paired serum

† HFMD becomes a notifiable disease in Thailand

In July 2006, the Thai Bureau of Epidemiology was notified of a cluster of four pediatric deaths occurring within a three-day period in non-contiguous districts of Nakhorn Ratchasima Province. The children all had clinical presentations compatible with enterovirus infection. We conducted an outbreak investigation to determine the etiology of infection and to identify any additional cases in the community.

## Methods

We reviewed both outpatient and inpatient medical records for each of the four fatal cases. The data obtained from the medical records were reviewed by a team of experts including an infectious disease pediatrician, a field epidemiologist, a microbiologist, and a sanitarian. In districts A and B in Nakhorn Ratchasima Province, we conducted active case finding with village health volunteers in the two villages from each district in which cases occurred. We used a structured questionnaire and conducted the interviews before specimen collection.

The definition of a probable EV71 case was a child younger than 15 years old who developed fever (body temperature  $\geq 38.0^{\circ}\text{C}$ ) and/or HFMD, or a case of HFMD reported from the district hospital, during 5 Jul to 5 Aug 2006.

A confirmed case was a probable case with laboratory confirmation by at least one of the methods: positive viral isolation by cell culture of EV71, PCR confirmed EV71, fourfold rising of EV71 IgG in acute and convalescent phase serology, and electron microscope evidence of viral-like particle infiltration of the autopsy tissue compatible with enterovirus species and epidemiological linkage with a confirmed case.

The laboratory investigation included viral isolation and PCR from stool specimens, throat swabs and nasopharyngeal swabs. We tested acute and convalescent sera with a microneutralization antibody assay for IgG antibody to EV71. Nucleotide sequencing was performed on EV71 isolates. With electron microscopy, formalin-fixed autopsy specimens of brain, heart and lung tissue were scanned to identify pathogen infiltration.

## Results

Through active case finding, we identified an additional eight confirmed and 30 probable cases.

Table 2. Characteristics of patients identified through active case finding, Nakhorn Ratchasima Province, Thailand, 2006 (N=24)

Disease	District A N (%)	District B N (%)
HFMD	12 (50)	0 (0)
Febrile illness	11 (46)	14 (100)

Twelve were diagnosed with HFMD, clinical characteristics of cases found through active case finding in table 2. The epi-curve is presented in figure 1. Most cases occurred in district A.

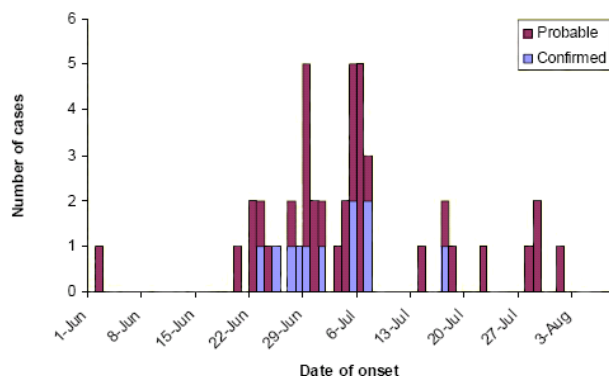


Figure 1. Epidemic curve of probable and confirmed cases of EV71 infection, Nakhorn Ratchasima Province, Thailand, 2006 (N = 42)

Four out of 42 total cases were fatal (case fatality proportion 9.5%). None of the four fatal cases were diagnosed with HFMD. Clinical and demographic details of the fatal cases are presented in table 3.

Table 3. Demographic, laboratory and clinical characteristics of two fatal confirmed, and two fatal probable cases of EV71, Nakhorn Ratchasima Province, Thailand, 2006

Characteristic	Case 1	Case 2	Case 3	Case 4
Sex	Female	Male	Male	Male
Age (months)	4	24	17	39
Village	X	X	Y	Z
District	A	A	B	B
Onset date	25 Jun	23 Jun	22 Jun	24 Jun
Length of fever (days)	3	34	2	3
Length of illness until died (days)	4	3	3	4
High grade fever (>39°C)	Yes	Yes	Yes	Yes
Acute dyspnea	Yes	Yes	Yes	Yes
URI symptoms	No	No	No	Yes
GI symptoms	Yes	Yes	Yes	Yes
HFMD	No	No	No	No
Chest X-ray	Pulmonary edema	Pulmonary edema	Pulmonary edema	Pulmonary edema
EV71 isolation	No specimen	EV71	No specimen	No specimen
Autopsy & electron microscopy	Enteroviral-like particles in brain tissue	Not done	Not done	Not done
Case classification	confirmed	confirmed	probable	probable

URI = Upper Respiratory Tract; GI = Gastrointestinal; HFMD = Hand, Foot and Mouth Disease

Two of the four fatal cases were laboratory confirmed and were linked epidemiologically; they

had a history of close contact, i.e., hugging, kissing and holding each other's milk bottles.

Electron microscopy of autopsy tissue samples from fatal case 1, four-month-old female, conducted at the Department of Microbiology, Faculty of Medicine Siriraj Hospital, Mahidol University revealed spherical, non-enveloped, viral-like particles, with an average diameter of 20 nm. Some of the particles were in membrane-bound vesicles and some were scattered in the cytoplasmic matrix (Figure 2).

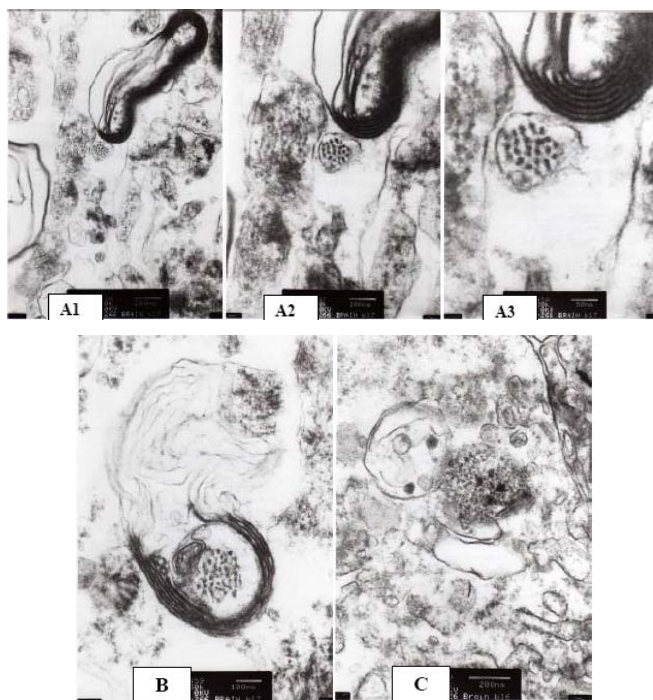


Figure 2. Electron microscopy of brain tissue from a four-month-old case of EV71, Department of Microbiology, Faculty of Medicine and Siriraj Hospital, Mahidol University, Bangkok, Thailand, 2006

No viral particles appeared in the cardiac or lung tissue. Sequencing of EV71 isolated from fatal Case 2, two-year-old boy, was done at the same facility and identified the sample as the sub-genogroup C4:Shenzhen strain (Genbank Locus number: EF203407), a strain first identified in Mainland China<sup>9</sup>.

Five of the 32 probable cases (15.6%) had non-EV71 viruses isolated from their samples because they met our probable case definition and kept our case fatality proportion estimate conservative we included them in our analysis.

## Discussion

Fatal EV71 infections are not a new occurrence in Asia. However, past fatal infections have occurred within large outbreaks. The case fatality proportions in the 1998 Taiwan outbreak (0.06%) and the 2006 Malaysia outbreak (0.09%) were dramatically lower than the 9.5% observed in our investigation. Another remarkable feature of this outbreak was the absence of HFMD signs and symptoms in the majority of cases. Our investigation was limited in geography (two districts) and in overall scope (42 cases), but if clusters of fatal EV71 cases persist outside the

context of large-scale HFMD outbreaks, then a new epidemiological profile may be emerging for EV71 infection. EV71 Subgroup C4 was first isolated in China<sup>9</sup> and has since been isolated in Taiwan<sup>10</sup> and in Japan<sup>11</sup>. The EV71 C4:Shenzhen strain identified in our outbreak has not previously been found in Thailand<sup>9</sup>. The appearance of this strain led us to ask relatives of the fatal cases about travel history.

The grandmother of Case 1 traveled to China and Singapore in May 2006, one month prior to the fatal events. She had close contact with Case 1 and it is possible that she was the index C4:Shenzhen strain infection with asymptomatic disease. After this outbreak, EV71 was found in other parts of Thailand. Genogroup C4 was isolated from three children with severe febrile illness, two of whom died (personal communication). The significance of the association between the high case fatality proportion we observed and this strain is unclear at this time.

This investigation was limited by the low proportion of cases with laboratory confirmation, present in only two of the fatal cases. We chose to include probable cases in our analysis because that provided the most conservative case fatality proportion calculation.

#### Public Health Action and Recommendations

Standard control measures including improvement of personal hygiene, especially hand washing before eating and after going to the bathroom, and encouraging isolation of sick children at home, were implemented in districts A and B. Pediatricians and general practitioners in the community were asked to be aware of possible severe EV71 infection manifesting without skin lesions.

A new national surveillance system was set up for pediatric cases of fever and pulmonary edema or acute respiratory distress syndrome in July 2006<sup>12</sup>. The new system includes a comprehensive review and investigation of every fatal case and aims to: 1) describe the magnitude and trends of epidemic, severe HFMD and non-HFMD fever with pulmonary edema; 2) identify etiological agent(s) especially EV71; 3) identify risk factor(s) of severe case(s); and 4) implement control and prevention measures<sup>12</sup>. Careful monitoring of the new surveillance system's results and ongoing sequencing of EV71 isolates are necessary to better understand the magnitude of the danger of EV71 infection in Thailand.

#### Acknowledgments

We thank all the local staff at Nakhorn Ratchasima Provincial Health Office, Maharaj Nakhorn Ratchasima Regional Hospital and Srikue Community Hospital for their valuable support in various activities that led to our accomplishment in the investigation. We also thank Dr. Suchitra Nimmanitya for helpful review of the manuscript.

#### Suggested Citation

Buathong R, Hanshoaworakul W, Sutdan D, Iamsirithaworn S, Pongsuwanna Y, Puthawathana

P, et al. Cluster of fatal cardiopulmonary failure among children caused by an emerging strain of enterovirus 71, Nakhorn Ratchasima Province, Thailand, 2006. OSIR. 2008 Aug;1(1):1-3. <<http://www.osirjournal.net/issue.php?id=5>>.

#### References

1. Ho M, Chen ER, Hsu KH, et al. An epidemic of enterovirus infection in Taiwan. *N Engl J Med*. 1999;341:936-42.
2. A-Lan B. Malaysia: Hand, foot and mouth disease cases in Sarawak Reach 13,800. *ProMED* 20060821.2355. <<http://www.promedmail.org>>.
3. Wu JM, Wang JN, Tsai YC, et al. Cardiopulmonary manifestations of fulminant enterovirus 71 infection. *Pediatrics*. 2002;109(2):26.
4. Mandell GL, Bennett JE, Dolin R. Principles and practice of infectious diseases. 5th ed. Churchill Livingstone; 2000.
5. Behrman RE, Kliegman RM, Jenson HB. Nelson textbook of pediatrics: Nonpoliovirus. 17th ed. Saunders; 2004.
6. Bureau of Epidemiology, Ministry of Public Health, Thailand. Annual epidemiological surveillance report (WESR) 2001-2005.
7. Lu CY, Lee CY, Kao CL, et al. Incidence and case-fatality rates resulting from the 1998 enterovirus 71 outbreak in Taiwan. *J Med Virol*. 2002;67:217-23.
8. Ooi EE, Phoon MC, Ishak B and Chan SH. Seroepidemiology of human enterovirus 71, Singapore. *Emerg Infect Dis*. 2002;8(9):995-7.
9. Hiroyuki S, Andi U, Napa O, et al. Molecular epidemiology of enterovirus 71 infection in the Western Pacific region. *Pediatr Int*. 2004;46:231-35.
10. Li L, He Y, Yang H, et al. Genetic characteristics of human enterovirus 71 and coxsackievirus A16 circulating from 1999 to 2004 in Shenzhen, People's Republic of China. *J Clin Microbiol*. 2005 August; 43(8): 3835-3839.
11. Mizuta K, Abiko C, Murata T, et al. Frequent importation of enterovirus 71 from surrounding countries into the local community of Yamagata, Japan, between 1998 and 2003. *J Clin Microbiol*. 2005;43(12):6171-5.
12. Bureau of Epidemiology, Ministry of Public Health, Thailand. Guideline for surveillance of fever with acute pulmonary edema in young children, *Weekly Epidemiological Surveillance Report (WESR)*. 2006;37(29): 509-10.